

REGENERATIVE THERAPY USING BOVINE BONE MINERAL SHOWS STABLE LONG-TERM RESULTS

A RETROSPECTIVE CLINICAL COHORT STUDY

241
OSTEOLOGY
MONACO 2013

Frank Bröseler¹, Christina Tietmann¹, Ann Kathrin Hinz¹, Søren Jepsen²

¹ Private Practice for Periodontology, Aachen/Germany

² Department of Periodontology, Operative and Preventive Dentistry, Univ.Bonn/Germany

Objective

The objective of this retrospective cohort study was to evaluate whether evidence from randomized clinical trials on the successful treatment of intrabony defects by regenerative therapy can be transferred to patients in a private periodontal practice.

Methods

In 191 patients a total of 1099 teeth with intrabony defects were treated using bovine bone mineral with or without collagen membrane. Defects were classified as 1- and 2-wall and as shallow (<6 mm), moderate (6-11 mm) and deep (>11 mm).

A total of **1008 defects in 176 patients** were monitored clinically and radiographically for collection of 1-year short-term, mid-term (2-4yrs) and long-term (5-10yrs) data. Baseline measurements were taken clinically and radiographically for standardisation of defect size. IMAGE J Software allows measurement accuracy of 0.01 mm.

During supportive periodontal therapy, measurements were recorded from 1y post-operative x-rays (N=1008) and at following investigation stages, up to 10 years (mean 5.2 years).

Change in radiographic bone levels was used as primary outcome parameter.

Due to lack of compliance or supportive care alio loco, 15 patients (91 teeth) were excluded from analysis.

Significant bone level change BL/t₁ and BL/t₃: p<0,005 shown in all defect types

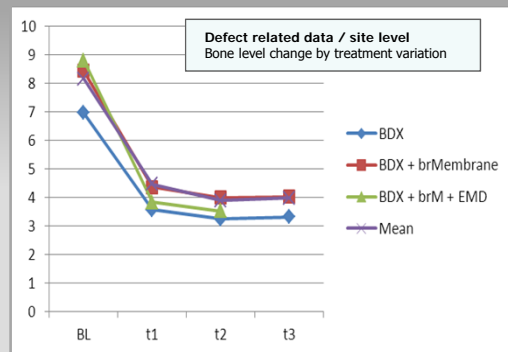
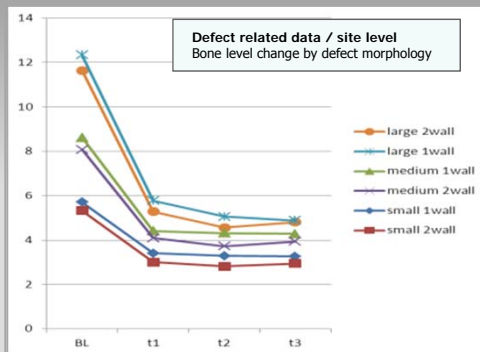
No significant bone level change shown for t₁/t₂, t₁/t₃, t₂/t₃

Interaction effects:

n.s. shown for smokers (29%)

n.s. shown for n.wall

n.s. shown for treatment variations



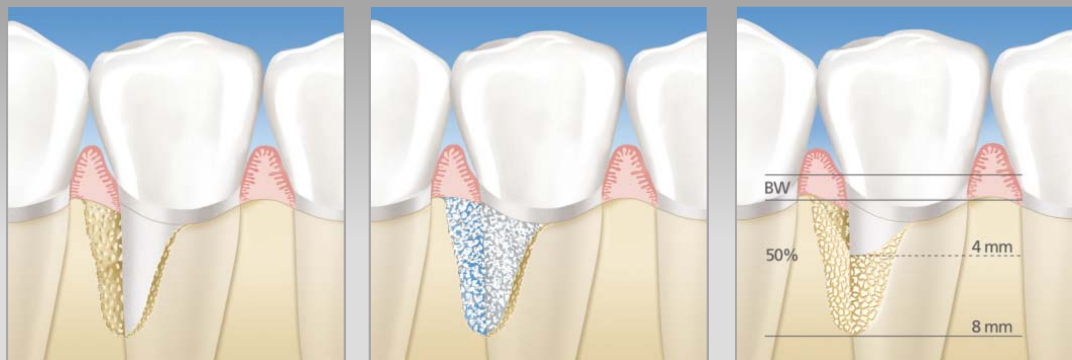Results

Patient related data
Long-term evaluation, most severe defects

$\Delta L_{abs} [t1/t3] = 5,04mm$
 $\Delta L_{med:rel} = 54,45%$

Significant bone level change BL/t₁ and BL/t₃: p<0,005 shown in patient related data

No significant bone level change shown for t₁/t₂, t₁/t₃, t₂/t₃



BW = biological width

Overall a mean **radiographic bone fill of >50% was observed**. Deep and moderate defects showed a higher degree of radiographic bone fill than shallow defects (54,5% vs. 50% vs. 43,3%). Radiographic bone gain obtained at 1year remained stable during mid-term and long-term follow-up.

Tooth loss amounted to 2.6% and was dependent on initial defect size (1.2% for shallow, 1.4% for moderate, 5.7% for deep defects) and occurred mainly due to endodontic failures.

Conclusions

Under conditions of daily periodontal practice, regenerative treatment using bovine bone mineral with or without collagen membrane can lead to a mean defect resolution of greater than 50%, based on radiographic (2D) measurement. A 3D defect reconstruction of approximately 75% can be assumed from this finding. The radiographic bone gain achieved at 1y post-operatively could be maintained up to 10 years after surgical intervention in patients with compliance to periodontal supportive care.

References: 1. Cortellini P, Tonetti MS. Long-term tooth survival following regenerative treatment of intrabony defects. J Periodontol 2004;75:672-678. | 2. Pretz B, Kim T-S, Holle R, Eickholz P. Long-term results of guided tissue regeneration therapy with non-resorbable and bioabsorbable barriers. IV. A case series of intrabony defects after 10 years. J Periodontol 2008b;79:1491-1499. | 3. Sculean A, Schwarz F, Chiantella GC, Donos N, Arweiler NB, Brex M, Becker J. Five-year results of a prospective, randomized, controlled study evaluating treatment of intra-bony defects with a natural bone mineral and GTR. J Clin Periodontol 2007;34:72-7. | 4. Silvestri M, Rasperini G, Milani S. 120 Infrabony defects treated with regenerative therapy: long-term results. J Periodontol 2011;82:668-75. | 5. Stavropoulos A, Karring T. Long-term stability of periodontal conditions achieved following guided tissue regeneration with bioresorbable membranes: case series results after 6-7 years. J Clin Periodontol 2004;31:939-944.

Special thanks to Dr. M. Mayer, Bern/CH for statistical analyses and Peter Quirin, Wiesbaden/DE for graphical work. The authors declare that they have no conflict of interest

Corresponding author: Dr. Frank Bröseler
ZAHNÄRZTLICHE PRAXIS FÜR PARODONTOLOGIE
Krefelder Straße 73, 52070 Aachen, Germany
praxis@paro-aachen.de



ZAHNÄRZTLICHE PRAXIS FÜR PARODONTOLOGIE
Dr. med. dent. FRANK BRÖSELER
Dr. med. dent. CHRISTINA TIETMANN
Krefelder Straße 73, 52070 Aachen, Germany | www.paro-aachen.de