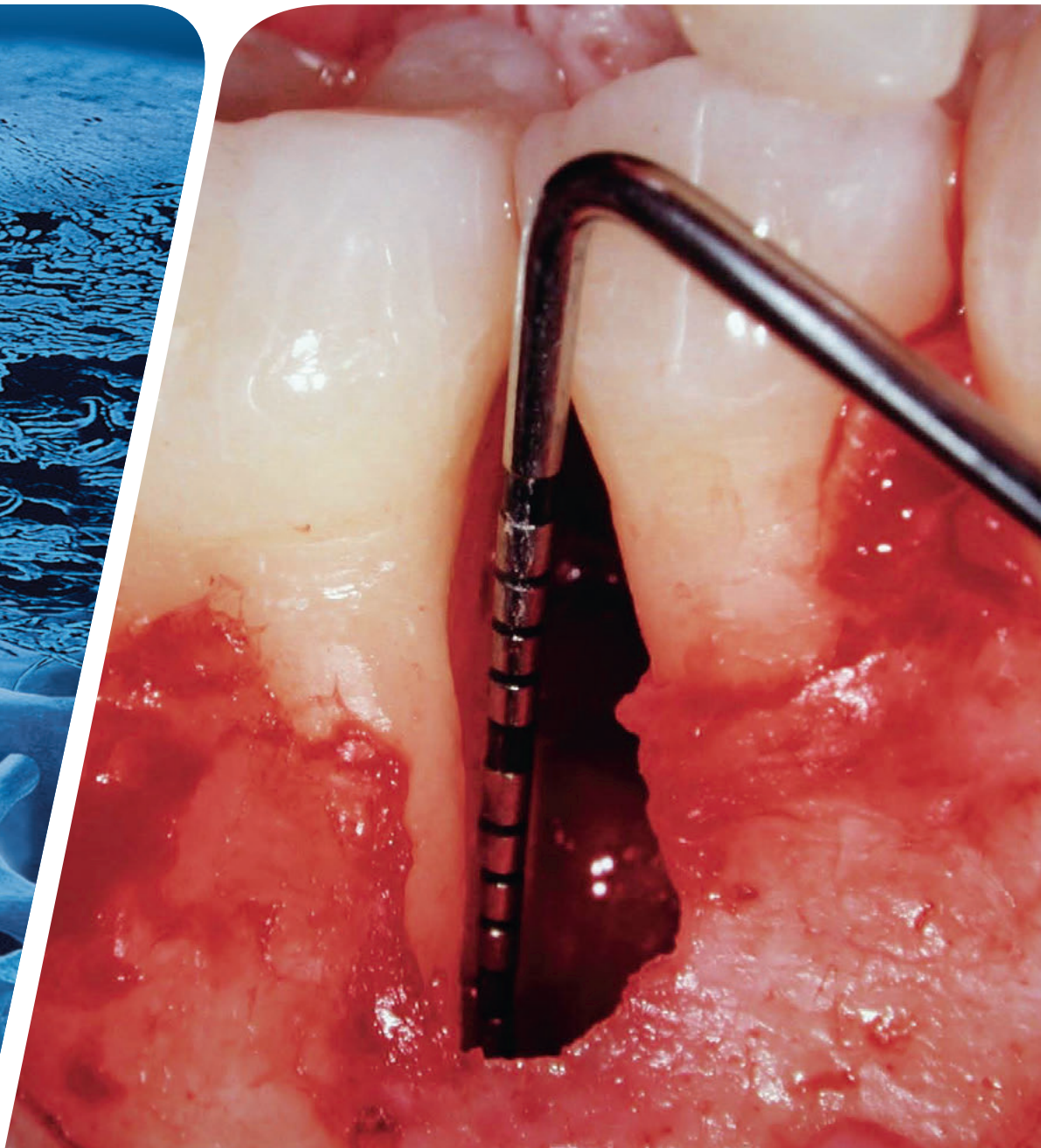



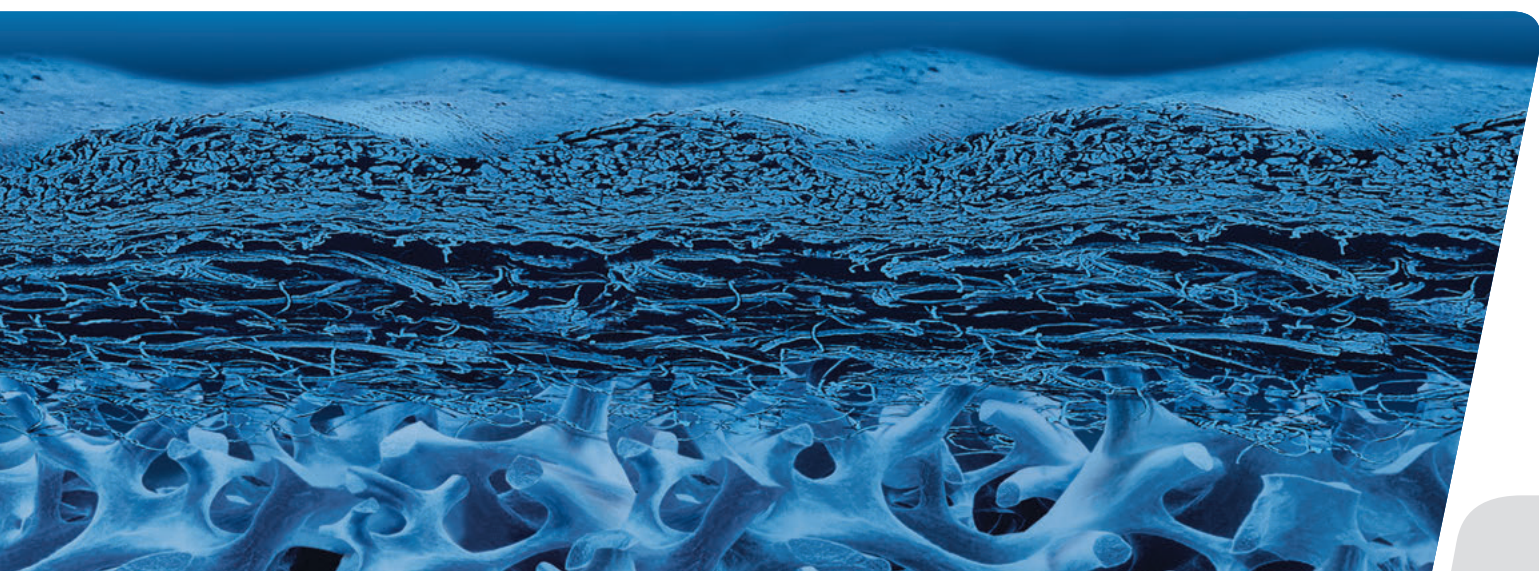
# Treatment Concepts

for Periodontal Regenerative Surgery



# Content

Why periodontal regeneration?	3
Regenerative therapy: getting to the root of the problem	4
Suggested treatment concept for periodontally compromised teeth	5
Defect morphology influences outcome of regenerative therapy	6
Scientific and clinical evidence for the surgical preservative phase	7
Case 1: Dr. Frank Bröseler   Intrabony 2-wall defect: interproximal crater	8
Case 2: Dr. Diego Capri   3-wall defect: rapid progression of lesion	9
Case 3: Prof. Dr. Michael Christgau   Extended 2-wall defect	10
Case 4: Dr. Pierpaolo Cortellini   Periodontal regenerative surgery	11
Case 5: Dr. Daniel Etienne   Treatment of infrabony 1-wall defect	12
Case 6: Prof. Dr. Markus Hürzeler   Combination defect	13
Case 7: Dr. Syed Mahnaz   Regenerative surgery 11 – perio-endo	14
Case 8: Prof. Dr. Giulio Rasperini   2-wall defect in the non-aesthetic region	15
Case 9: Prof. Dr. Anton Sculean   Deep intrabony 2-wall defect	16
Case 10: Dr. Beat Wallkamm   2-wall defect in the aesthetic zone	17
Case 11: Prof. Dr. Giovanni Zucchelli   2-wall wide intrabony defect	18
References	19
Product Range for periodontal treatment	20





## Why periodontal regeneration?

Helping patients affected by periodontitis to create and maintain good oral health, function, and aesthetics is the goal of every dentist. To accomplish this, various therapeutic approaches have been developed in response to the grades of severity of periodontitis. The role of biomaterials in treating periodontal disease has gained in significance and is now an integral part of many protocols. Carefully selected biomaterials used with proven treatment protocols may not only stop progression of periodontal disease, but effectively regenerate both hard and soft tissue.<sup>1,2</sup>

The present treatment concept serves to summarise proven Guided Bone Regeneration (GBR) and Guided Tissue Regeneration (GTR) techniques for the successful treatment of common periodontal defects.

It provides scientific evidence and presents step-by-step clinical cases, demonstrating stable favorable outcomes. This guide is intended for the clinician and highlights reliable treatment options with the highest quality biomaterials. It aims to present techniques and tools used for oral tissue regeneration to offer optimised therapy, leading to greater patient long-term satisfaction.<sup>2</sup>

**TABLE 1.** Prognosis of periodontally affected teeth: For classification at least one of the parameters (respectively two for hopeless teeth) has to be met.<sup>6-8</sup>

<b>GOOD</b>	<b>QUESTIONABLE</b>	<b>HOPELESS</b>
<ul style="list-style-type: none"> <li>&gt; teeth with &lt; 50% bone loss</li> </ul>	<ul style="list-style-type: none"> <li>&gt; teeth with 50-75% bone loss or</li> <li>&gt; 6–8 mm PD or</li> <li>&gt; class 2 furcation or</li> <li>&gt; angular defect</li> </ul>	<ul style="list-style-type: none"> <li>&gt; teeth with &gt; 75% bone loss or</li> <li>&gt; more than 8mm PD or</li> <li>&gt; Class 3 furcation or</li> <li>&gt; Class 3 mobility or</li> <li>&gt; teeth with at least 2 characteristics of questionable category</li> </ul>

### TOOTH PRESERVATION OR IMPLANT?

Teeth will last for life, unless they are affected by oral diseases or service interventions. Many retained teeth therefore may be an indicator of positive oral health behaviour throughout the life course. Tooth longevity is largely dependent on the health status of the periodontium, the pulp or periapical region and the extent of reconstructions.<sup>3</sup> Multiple risks lead to a critical appraisal of the value of a tooth. Choosing between periodontal regeneration to support tooth preservation and tooth extraction has been called one of the most complex and debatable decisions a dentist is confronted with in daily clinical practice.<sup>4</sup> Assigning a questionable prognosis – where the tooth requires advanced treatment to maybe preserve it –

or a hopeless prognosis, where the tooth needs to be extracted as soon as possible, is often a delicate situation. This decision significantly impacts both treatment planing and patient lifestyle. Accordingly, it has been argued that periodontally compromised teeth should be treated for as long as possible, and only being extracted when periodontal and endodontic treatment is no longer possible.<sup>4,5</sup> Regardless of whether the tooth is preserved or extracted, biomaterials are often required to reach the individual therapeutic goals. Some criteria to categorise the prognosis of periodontally affected teeth are summarised in Table 1.<sup>6-8</sup>

## Regenerative therapy: getting to the root of the problem

Good – Questionable – Hopeless ... now what?

In advance of any regenerative therapy, an initial non-surgical hygienic phase is crucial. This may include patient education on oral hygiene, scaling and root planing, antibacterial therapy, and removal of plaque retentive factors – all aimed to yield a good tissue response by eliminating infection and alleviating inflammation. When these methods fail to prevent bone loss, surgical or even regenerative therapy for periodontally compromised teeth is the recommended next-line therapy (Figure 2).<sup>9-11</sup>

In questionable cases, regenerative therapy may be favored over tooth extraction. This because extracting periodontitis-affected teeth will not resolve the underlying host response-related problems contributing to the disease.

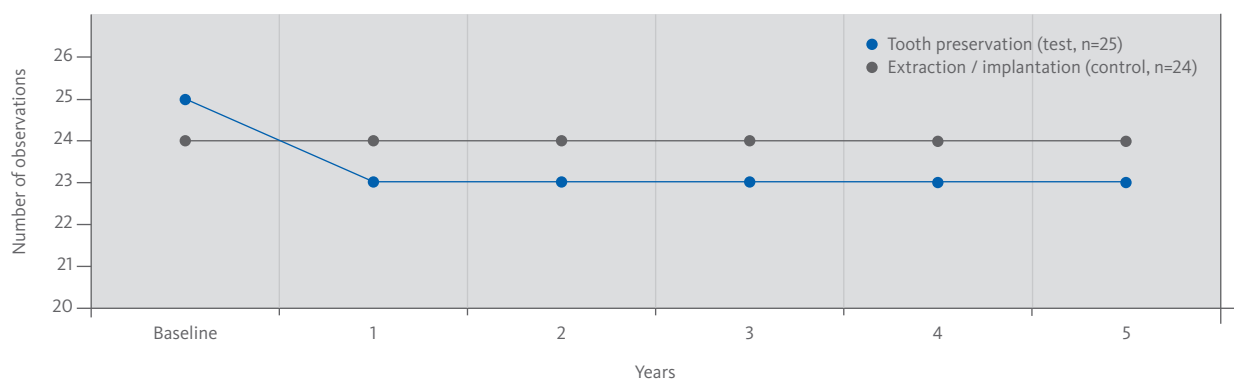
Moreover, periodontally compromised but treated teeth are known to have survival rates equal to the survival rates of implants in well-maintained patients.<sup>12</sup>

A growing amount of evidence indicates that periodontal regeneration can result in long-term retention of teeth originally presenting with deep pockets associated with intra-bony defects.<sup>12-15</sup> A randomised, long-term clinical trial in 50 patients comparing periodontal regeneration with extraction and prosthetic replacement of hopeless teeth showed that regenerative therapy enabled retention of 92% “hopeless” teeth scheduled for extraction.<sup>7</sup>

The retained teeth had clinically stable periodontal parameters, comfort and function for the follow-up period of 5-years (Figure 1).<sup>12</sup>

### AIMS OF REGENERATIVE TREATMENT

- > Restoration of the complete tooth attachment apparatus with bone, cementum, and ligament
- > Prevention of long junctional epithelial down growth as a risk factor for recurrence of periodontitis
- > Long-term tooth retention
- > Aesthetic appearance



**FIGURE 1.** Survival analysis. Comparison between hopeless teeth (test group) treated with periodontal regeneration and implant supported teeth at extraction sites of hopeless teeth (control group). Survival at 5 years was 100% in the control group versus 92% in the test group.<sup>12</sup>

# Suggested treatment concept for periodontally compromised teeth

THE FOLLOWING TREATMENT PLAN OUTLINES A POSSIBLE CLINICAL METHODOLOGY:

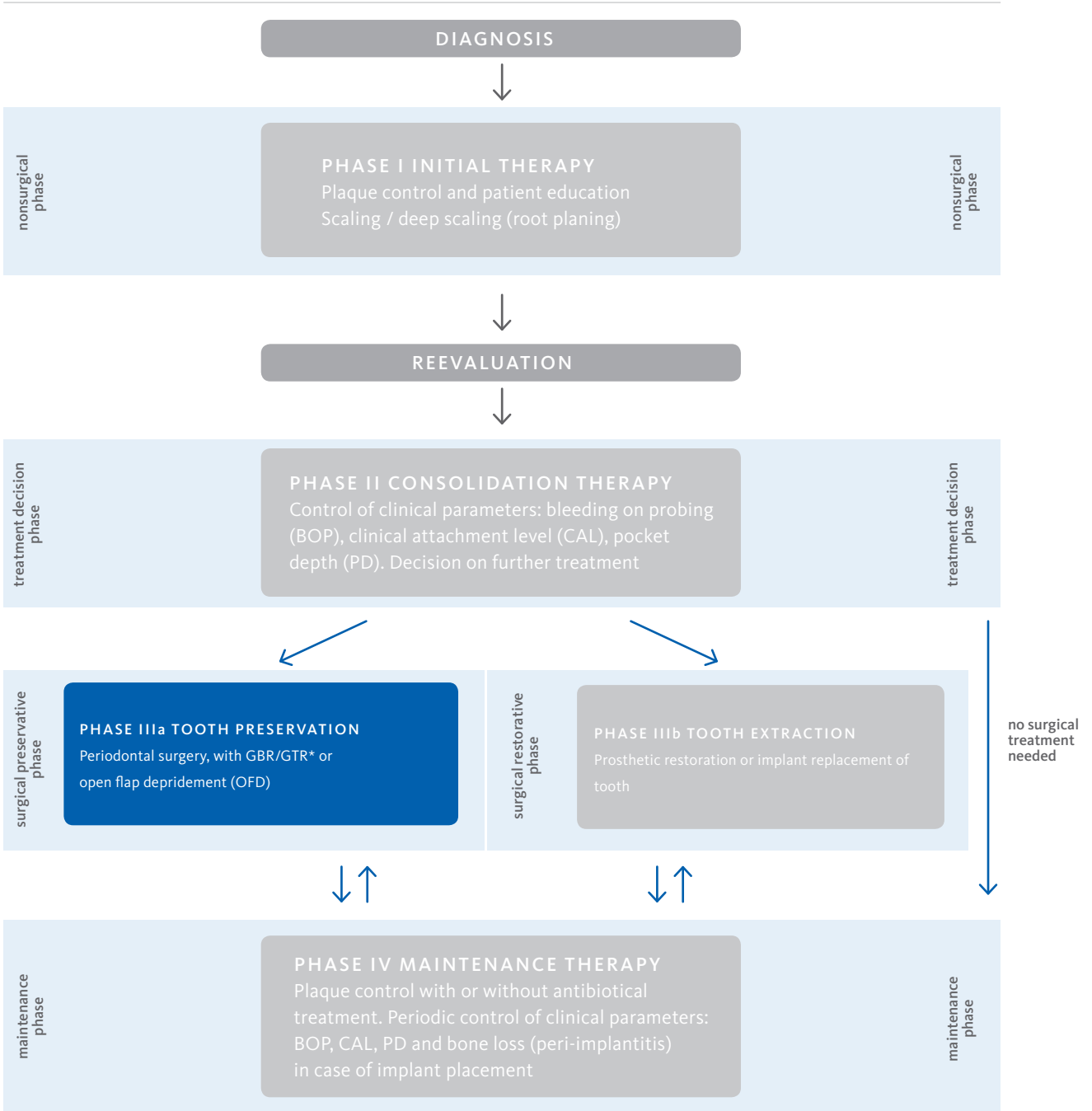


FIGURE 2. Suggested Treatment Concept (Adapted from Newman, Lindhe, Rateitschak<sup>9-11</sup>)

\* the present Treatment Concept presents only cases with GBR/GTR

# Defect morphology influences outcome of regenerative therapy

There is a wide range of general factors that are known or assumed to influence periodontal healing (e.g., age, smoking, concomitant medication, postsurgical care, periodontal maintenance, oral hygiene, nutrition, stress).

Furthermore, defect morphology is a key factor for the therapy outcome.<sup>16</sup> Each periodontal osseous lesion presents a unique anatomy. A first level of classification differentiates between horizontal, infrabony, and furcation defects as represented in Figure 3.<sup>17</sup>

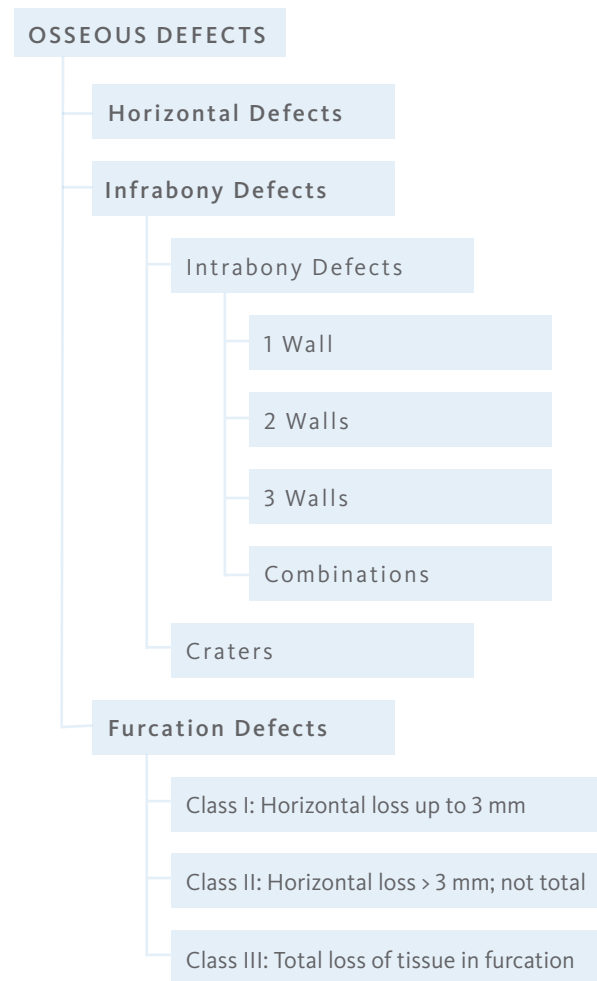
Horizontal defects are defined when the base of the pocket is located coronal to the alveolar crest whereas infrabony defects are apical (vertical defects).

Regenerative therapy (GBR, GTR) is indicated in bony defects with three, two or at least one remaining walls. To some extent also Class II furcation defects can be treated with GTR.<sup>18</sup> There is evidence, that 2- and 3 wall intrabony defects respond better to GTR therapy than 1-wall defects. However, the deeper the infrabony defect, the more attachment gain and bony fill may be expected.<sup>16</sup> Other defect characteristics influencing outcomes of regenerative therapy are presented in Table 2:

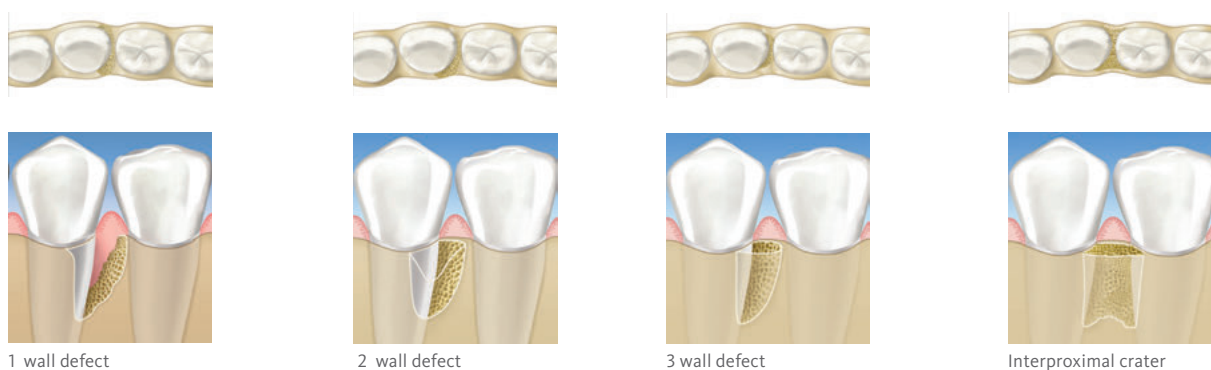
**TABLE 2:** Positive and negative defect characteristics<sup>16</sup>

POSITIVE INFLUENCE	NEGATIVE INFLUENCE
> Deep infrabony component (> 3 mm)	> Shallow infrabony component ( $\leq$ 3 mm)
> Narrow radiographic defect angle	> Wide radiographic defect angle
> Deep baseline pocket depth	> Tooth motility

The present Treatment Concept shows different cases that have been appointed to a classification system combining the remaining walls and the vertical dimension of the bony defect (Figure 4).



**FIGURE 3.** Classification of periodontal osseous defects (modified from Papapanou et al. 2000)<sup>17</sup>



**FIGURE 4.** Infrabony defects (modified from Papapanou et al. 2000)<sup>17</sup>

# Scientific and clinical evidence for the surgical preservative phase

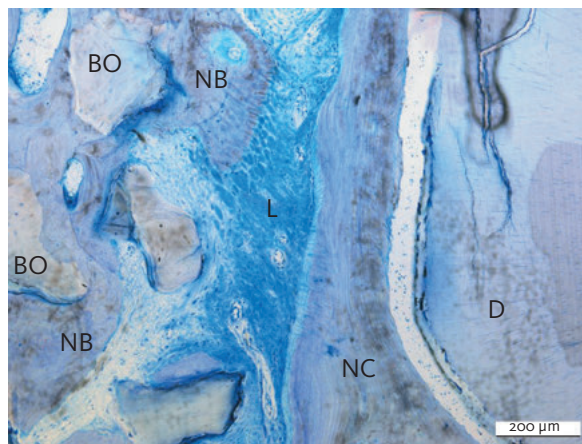
Upon decision to preserve the tooth, the next step is to decide for a surgical therapy: Leading treatment methods often utilise a combination of a slowly resorbing osteoconductive bone substitute and a membrane.<sup>19</sup>

## GUIDED TISSUE REGENERATION

Some evidence shows, that Guided Tissue Regeneration (GTR) is superior to Open Flap Debridement (OFD) for the treatment of periodontal intrabony and furcation defects.<sup>20-22</sup> Overall, GTR is consistently more effective than OFD in reducing:

- > open horizontal furcation depths,
- > horizontal and vertical attachment levels, and
- > pocket depths for mandibular or maxillary class II furcation defects.

With the use of Geistlich Bio-Oss<sup>®</sup> orthodontic movement is possible in patients after GTR therapy.<sup>23,24</sup> Moreover, resorbable membranes have proven superior to non-resorbable membranes in generating vertical bone fill.<sup>15</sup>



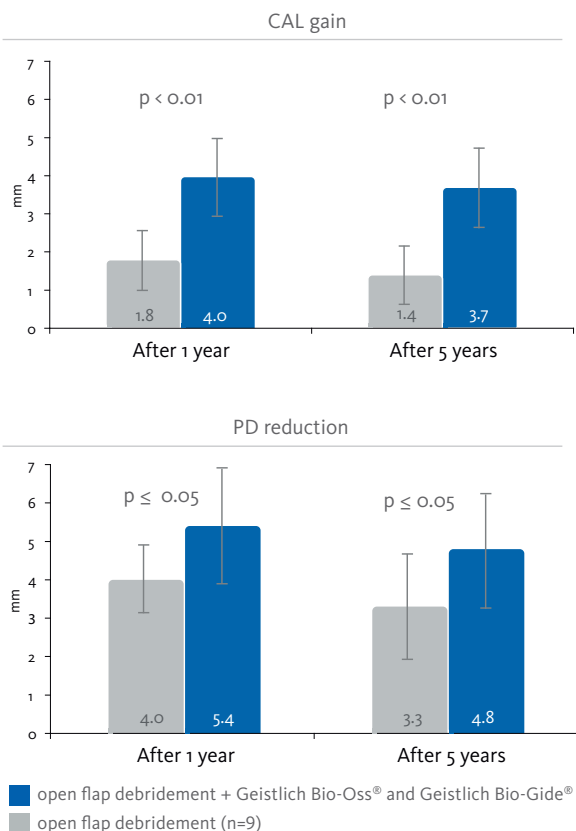
**FIGURE 6.** The histologic assessment demonstrates the presence of new periodontal ligament, cementum, and bone. The newly formed woven bone can be observed maturing into bone trabeculae completely surrounding Geistlich Bio-Oss particles. BO=Bio-Oss; NB=new bone L=ligament; NC=new cementum; OC=old cementum; D=dentin<sup>19</sup>

## GEISTLICH BIO-OSS<sup>®</sup> (COLLAGEN) AND GEISTLICH BIO-GIDE<sup>®</sup> (PERIO)

Combined filling of periodontal defects with the graft material Geistlich Bio-Oss<sup>®</sup> Collagen or Geistlich Bio-Oss<sup>®</sup> followed by Geistlich Bio-Gide<sup>®</sup> membrane coverage has a history of proven effectiveness in regenerative periodontal therapy.<sup>25-31</sup>

Treatment of intra-bony defects with Geistlich Bio-Oss<sup>®</sup> and Geistlich Bio-Gide<sup>®</sup> Perio resulted in sustained higher clinical attachment level gain as compared to treatment with OFD alone after 5 years (Figure 5).<sup>2</sup>

First clinical and histological results of treatment of endodontic-periodontic lesion with endodontic therapy followed by Guided Tissue Regeneration with Geistlich Bio-Oss<sup>®</sup> and Geistlich Bio-Gide<sup>®</sup> demonstrated that the combined approach can promote the formation of new cementum, periodontal ligament, and bone around the apex, as well as the complete bone regeneration of the buccal bone plate (Figure 6).<sup>19</sup>



**FIGURE 5.** The gain in clinical attachment level (CAL) and the reduction in pocket depth (PD) are significantly larger in the test group than in the control group respectively, ( $p=0.01$  and  $\leq 0.05$  respectively) both after one year and after 5 years.<sup>2</sup>

# Intrabony 2-wall defect: interproximal crater

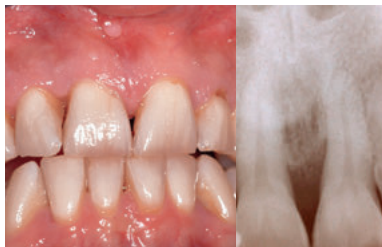SURGERY BY DR. FRANK BRÖSELER, AACHEN (DE)



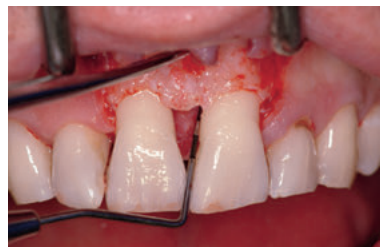**AIM** Functional and esthetic reconstruction in chronic periodontitis with deep intrabony defects.

Tooth #	CAL (mm)	PD (mm)	Depth of bony defect (mm)	Defect morphology
11	mesial 10	mesial 10	10	interproximal crater
21	buccal 6    mesial 10	buccal 5    mesial 10	9	

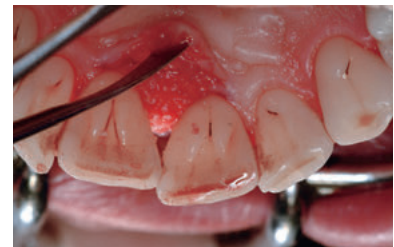<b>Biomaterials</b>	> Geistlich Bio-Oss® Collagen and Geistlich Bio-Gide® Perio.
<b>Suture material</b>	> 4-0 classic and 6-0 monofilament with cutting needle
<b>Technique</b>	> Full thickness flap, split released, papilla preservation
<b>Periodontal treatment</b>	> Patient instruction and plaque control for at least 8 weeks.



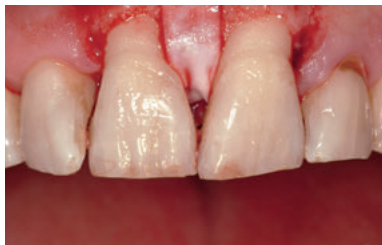**01** Initial situation after anti-infective therapy. Radiographically, the intrabony defect cannot be represented in toto due to palatal bone plate.



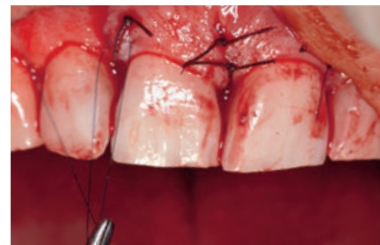**02** Intrasurgical situation after preparation of the mucoperiosteal full-thickness flap reveals deep osseous defect.



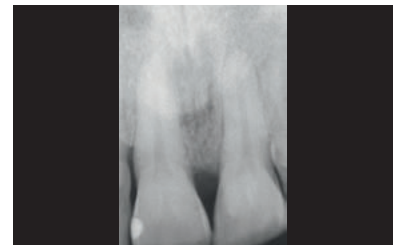
**03** Palatal view of the defect after application of Geistlich Bio-Oss® Collagen.



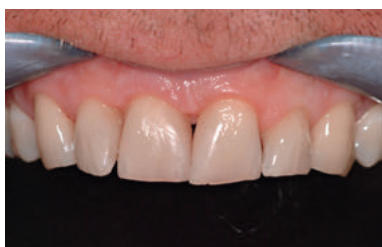**04** The grafted site is covered with Geistlich Bio-Gide® Perio.



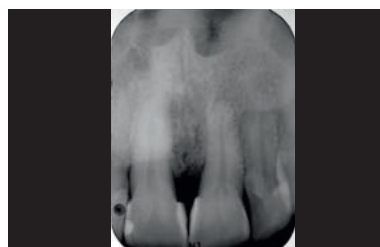
**05** The flap is repositioned and sutured to relieve flap tension and obtain primary closure of the interdental space.



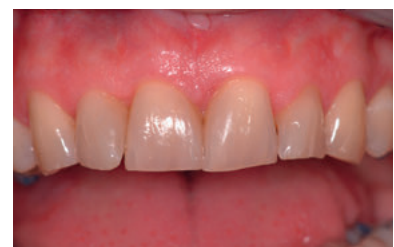**06** Postoperative x-ray control after regenerative procedure using Geistlich Bio-Oss® Collagen.



**07** Clinical situation at 3 years follow-up



**08** 4.5 years post-op radiograph showing sustained defect fill from Geistlich Bio-Oss® Collagen.



**09** Clinical situation at 7 years follow-up; note the naturally reformed papilla between the central incisors, and no gingival recession.

**CONCLUSION** After controlling the periodontal disease, this guided tissue regeneration technique leads to a long-term stable bony situation with pleasant soft-tissue appearance.



# 3-wall defect: rapid progression of lesion

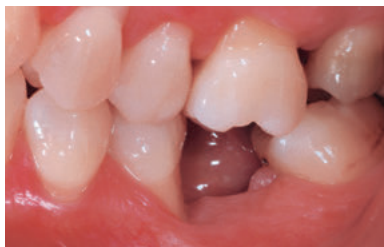SURGERY BY DR. DIEGO CAPRI, BOLOGNA (IT)



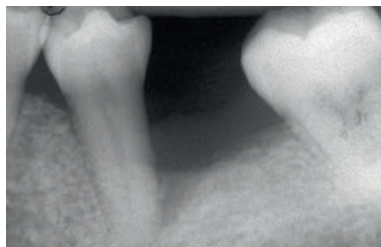
**AIM** Regeneration of a 2 to 3 wall defect caused by a cemental tear.

Tooth #	CAL (mm)	PD (mm)	Depth of bony defect (mm)	Defect morphology
35	distal 12	distal 7	5	3 wall defect
				without furcation

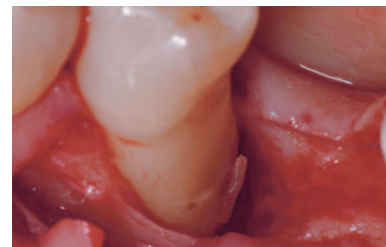
<b>Biomaterials</b>	> Geistlich Bio-Oss®, autogenous bone, Geistlich Bio-Gide®
<b>Suture material</b>	> Gore-Tex® Suture CV7
<b>Technique</b>	> Periodontal regeneration of the defect by means of GTR
<b>Periodontal treatment</b>	> Periodontal defect debridement with hand and ultrasonic instrumentation.



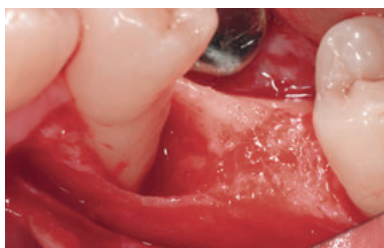
**01** Clinical preoperative view of the affected area showing the lesion.



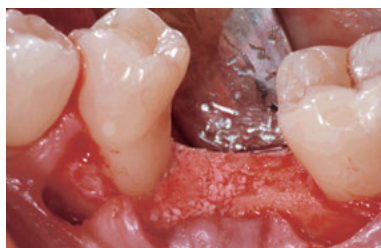**02** DIAGNOSIS: Cemental tear – likely caused by a parafunctional habit overlapped to partial edentulism and malocclusion in the area.



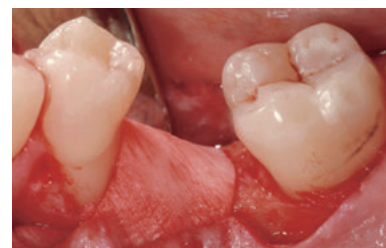**03** After reflection of a mucoperiosteal flap the periodontal defect is de-granulated and the fractured portion of the cementum is visible.



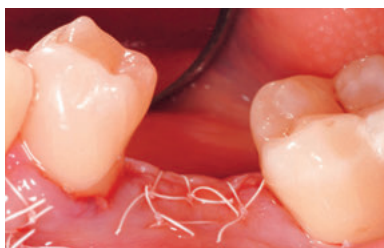**04** The root surface is thoroughly scaled and planed.



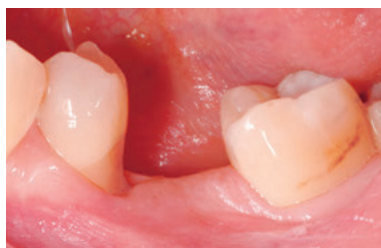**05** The defect is filled with a mixture of autogenous bone and Geistlich Bio-Oss®.



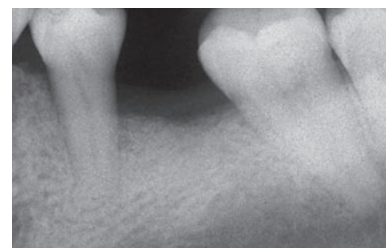
**06** A trimmed Geistlich Bio-Gide® collagen membrane is positioned on the augmented area.



**07** Primary wound closure is achieved, after proper releasing of the flap with internal mattress and single interrupted Gore sutures.



**08** 4 months after periodontal regenerative surgery a probing depth of 3 mm and a clinical attachment loss of 6 mm was measured distally.



**09** Intraoral radiographic aspect of the site showing the healing of the defect.

**CONCLUSION** The rapid progression of the lesion was arrested and the bone at the defect side successfully regenerated.

# Extended 2-wall defect

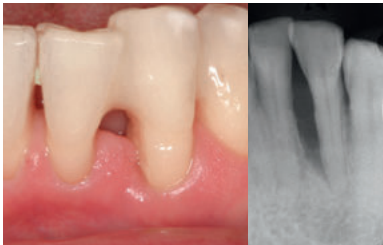
SURGERY BY PROF. DR. MICHAEL CHRISTGAU, DÜSSELDORF (DE)



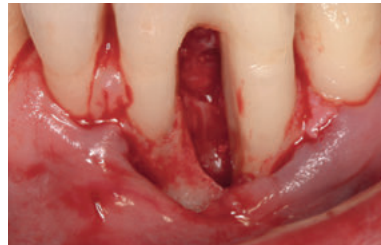**AIM** Defect resolution of an extended 2-wall defect with regenerative periodontal surgery.

Tooth #	CAL (mm)		PD (mm)		Depth of bony defect (mm)	Defect morphology
	mesial	distal	mesial	distal		
32	mesial 14	distal 4	mesial 11	distal 2	ca. 10	2 wall defect
	buccal 4	oral 4	buccal 1	oral 2		

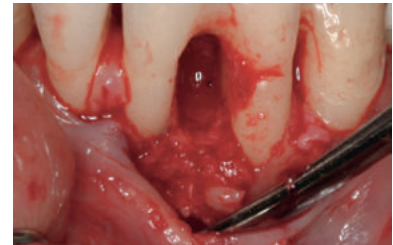<b>Biomaterials</b>	> Geistlich Bio-Oss® Collagen, Geistlich Bio-Gide® Perio, autogenous bone
<b>Suture material</b>	> Seralene® 5-0 and 6-0
<b>Technique</b>	> Papilla-Preservation technique, sulcular incision Regio 41–33 without vertical releasing incisions
<b>Periodontal treatment</b>	> Semipermanent adhesive tooth splinting with composite material and non-surgical periodontal therapy with additional systemic antibiotic therapy (3 x 400 mg metronidazol, 7 days)



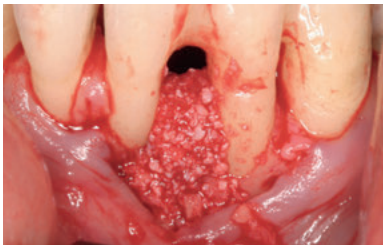
**01** Preoperative clinical and radiological situation showing an inflammation-free gingiva and the bone defect.



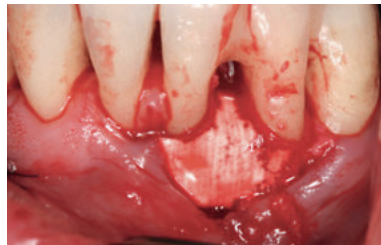
**02** Intraoperative view of the extended 2-wall defect.



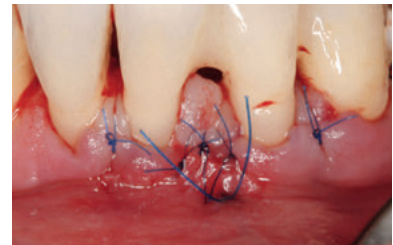
**03** Basal defect is filled with autogenous bone chips after debridement and root planing.



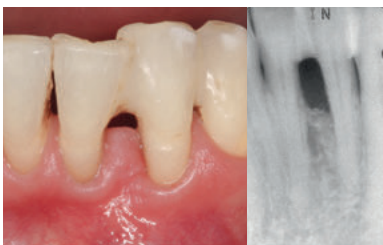**04** Autogenous bone covered and defect filled completely with Geistlich Bio-Oss® Collagen.



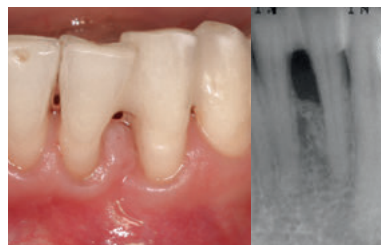**05** Coverage with a trimmed Geistlich Bio-Gide® Perio membrane without further fixation.



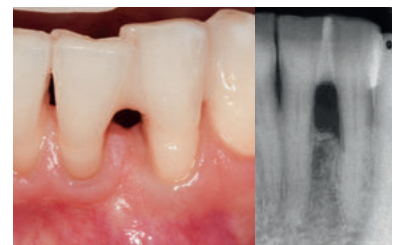
**06** Coronal flap repositioning and wound closure with horizontal mattress and single sutures.



**07** Clinical and radiological situation after 6 months with clinical attachment gain of 7 mm mesial and vast defect fill.



**08** Clinical and radiological situation at 12 months with clinical attachment gain of 8 mm mesial and considerable defect fill.



**09** Clinical and radiological situation 6 years after surgery showing stable long-term situation.

**CONCLUSION** Regenerative periodontal surgery with Geistlich Bio-Oss® Collagen and Geistlich Bio-Gide® Perio results in long-term defect resolution.

# Periodontal regenerative surgery

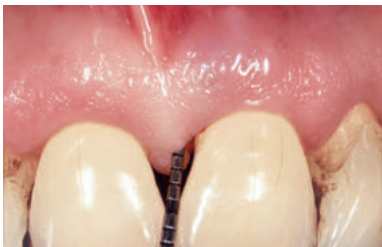SURGERY BY DR. PIERPAOLO CORTELLINI, FIRENZE (IT)



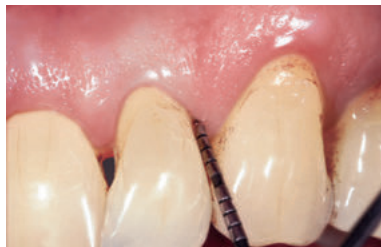**AIM** Resolution of deep pockets associated with deep intrabony defects and preservation of aesthetics on upper incisors.

Tooth #	CAL (mm)		PD (mm)		Depth of bony defect (mm)	Defect morphology
21 (22)	mesial 7 (4)	distal 2 (7)	mesial 6 (2)	distal 2 (6)	max. 10 (8)	2 wall defect
	buccal 4 (4)	lingual 3 (4)	buccal 4 (2)	lingual 3 (3)		without furcation

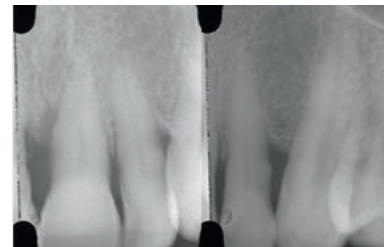
<b>Biomaterials</b>	> Geistlich Bio-Oss®
<b>Suture material</b>	> Gore-Tex® Suture 6-0
<b>Technique</b>	> Modified minimally invasive surgical procedure (M-MIST) with a Microblade USM 6900
<b>Periodontal treatment</b>	> Root planing was performed before surgery.



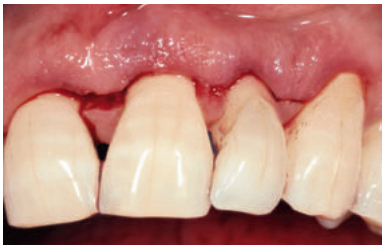**01** Preoperative probing at tooth 21 showing probing depth of 6 mm.



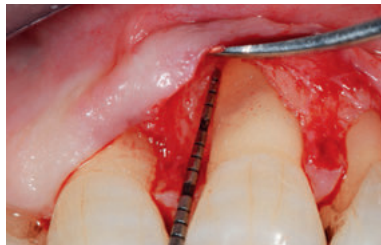**02** Preoperative probing at tooth 22 with probing depth of 6 mm.



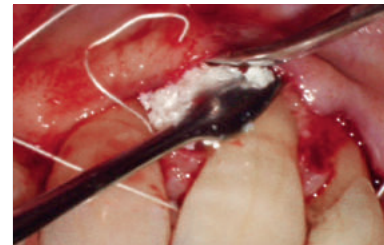
**03** Preoperative radiograph showing the intrabony defects mesial to tooth 21 and distal to tooth 22.



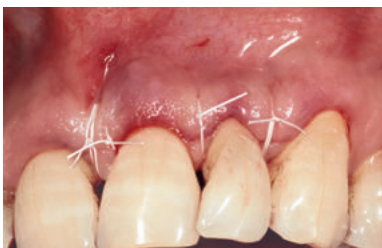**04** Buccal incision design.



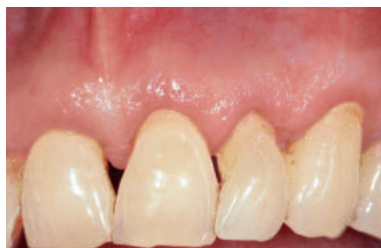**05** Intraoperative probing at tooth 21. Note the absence of the interdenal bone peak between teeth 11 and 21 and the severe buccal dehiscence. Geistlich Bio-Oss® was used to prevent the postoperative shrinkage of the soft tissues.



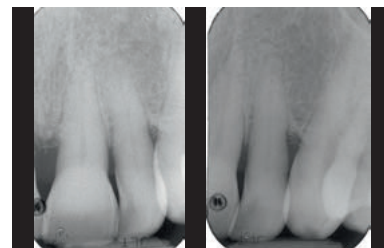
**06** Geistlich Bio-Oss® is positioned to fill the intrabony components of the defects. In larger and/or less contained defects, the additional use of a collagen membrane, such as Geistlich Bio-Gide®, is recommended.



**07** The flap is sealed over Geistlich Bio-Oss® with internal modified mattress sutures.



**08** 1 year clinical situation showing healthy condition and a minimal gingival recession relative to baseline.



**09** 1 year radiographs showing the resolution of the intrabony components of the defects.

**CONCLUSION** The combination of the modified minimally invasive surgical technique with Geistlich Bio-Oss® was effective in treating multiple intrabony defects associated with deep pockets in the upper incisors.

## References

Cortellini P, Tonetti MS. Improved wound stability with a modified minimally invasive surgical technique in the regenerative treatment of isolated interdental intrabony defects. *J Clin Periodontol* 2009; 36: 157–163.

Cortellini P, Tonetti MS. Clinical and radiographic outcomes of the modified minimally invasive surgical technique with and without regenerative materials: a randomized-controlled trial in intra-bony defects. *J Clin Periodontol* 2011; 38: 365–373.



# Treatment of infrabony 1-wall defect

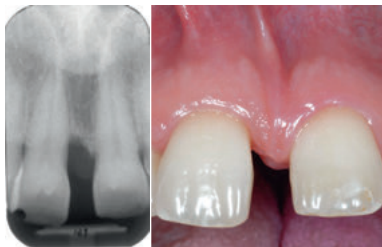SURGERY BY DR. DANIEL ETIENNE, PARIS (FR)  
NON SURGICAL PERIODONTAL THERAPY: DR. SOFIA AROCA, SAINT-GERMAIN EN LAYE (FR)



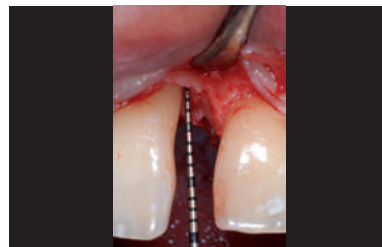**AIM** 1 wall periodontal defect treatment before orthodontic tooth intrusion and diastema closure.

Tooth #	CAL (mm)		PD (mm)		Depth of bony defect (mm)	Defect morphology
	mesial 6	distal 5	mesial 6	distal 5		
11 buccal	mesial 6	distal 5	mesial 6	distal 5	6	1-wall defect
11 lingual	mesial 6	distal 3	mesial 6	distal 3		without furcation

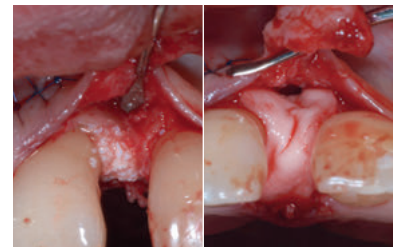
<b>Biomaterials</b>	> Geistlich Bio-Oss® small granules, Geistlich Bio-Gide® 25x25mm, Emdogain
<b>Suture material</b>	> 6-0 Ethicon PDS-II
<b>Technique</b>	> Remote palatal papilla incision and Guided Tissue Regeneration (GTR)
<b>Periodontal treatment</b>	> 1. Plaque control 2. GTR 3. Orthodontic treatment by Dr. Catherine Galletti (Paris)



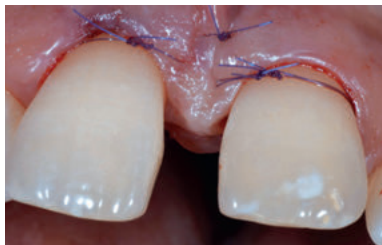**01** Preoperative clinical and radiological situation showing an angular bony defect at the mesial aspect of tooth 11. No inflammation of the soft tissue is observed. Presence of a diastema and a small papilla collapse mesial of 11.



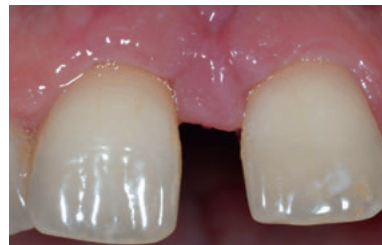**02** 1 wall defect of 6 mm CAL on mesio-buccal and mesio-lingual of 11.



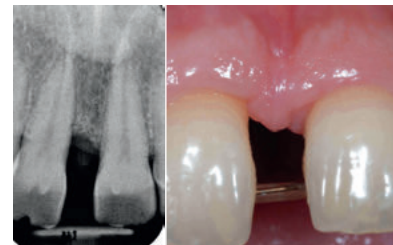**03** After debridement and root planing, root of tooth 11 is covered with Emdogain. Defect fill with Geistlich Bio-Oss® granules. The augmented site is covered with a Geistlich Bio-Gide® membrane.



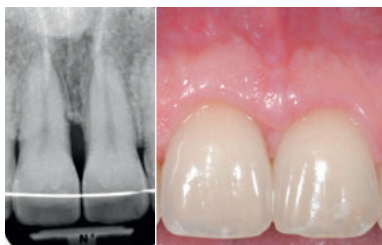
**04** Repositioning and suturing of the flap using 6-0 Ethicon PD-S II sutures.



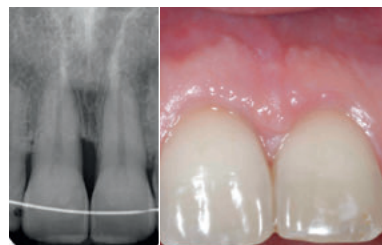
**05** Clinical situation 1 week after surgery and suture removal. No inflammation is observed.



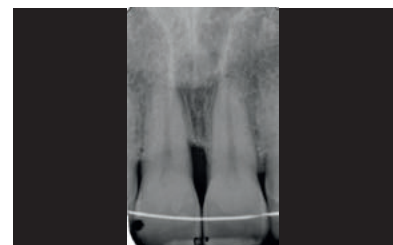**06** Clinical situation and x-ray of the augmented site just before start of orthodontic treatment 10 months after surgery.



**07** Clinical and radiological situation after orthodontic treatment (intrusion of 11 and diastema closure) and 3 years after surgery.



**08** Clinical and radiological images with stable tissue conditions 4 years after surgery.



**09** X-ray 5 years after surgery showing a slight and stable crestal bone remodelling in the mesial aspect of tooth 11.

**CONCLUSION** Slight crestal bone remodelling on the mesial aspect of tooth 11 was observed after orthodontic treatment, with 5 mm probing after papilla remodeling. Clinical attachment stability is observed during maintenance.



# Combination defect

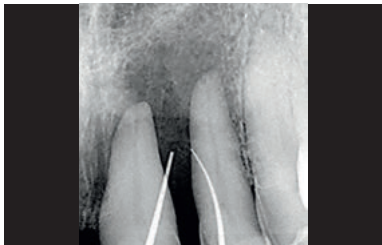SURGERY BY PROF. DR. MARKUS HÜRZELER, MÜNCHEN (DE)



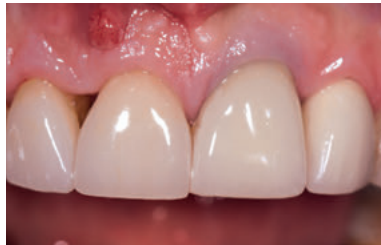**AIM** Periodontal regeneration of two teeth severely compromised by attachment loss at the apex.

Tooth #	CAL (mm)	PD (mm)	Depth of bony defect (mm)	Defect morphology
21, 11, 12	mesial 6,10,11 distal 6, 10, 7	mesial 6, 10, 11 distal 6, 10, 7	max 10	-
	buccal 5, 8, 9 lingual 5, 6, 7	buccal 5, 8, 9 lingual 5, 6, 7		

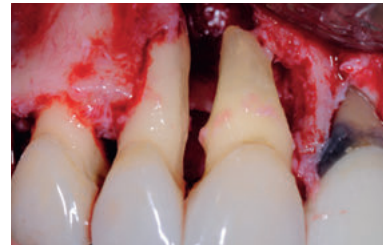
<b>Biomaterials</b>	> Geistlich Bio-Oss®, Geistlich Bio-Gide®, Amelogenin
<b>Suture material</b>	> Seralene® suture, DS 12, 15 / 7.0
<b>Technique</b>	> Microsurgical access flap with modified papilla incision technique
<b>Periodontal treatment</b>	> Anti-infectious therapy, Doxycyclin (Ligosan® Heraeus), DH (24 hours scaling), reevaluation, 11 + 21 Ca(OH) <sub>2</sub> and root canal filling 21, recall.



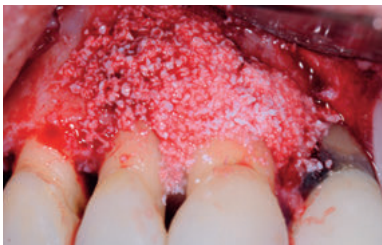
**01** Pre-operative radiological view of the extended bone loss.



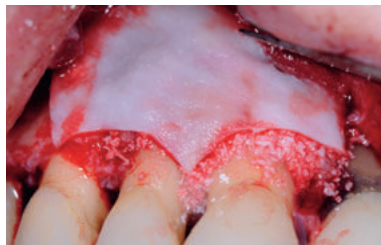
**02** Clinical situation preoperatively after Doxycyclin antibiotic treatment.



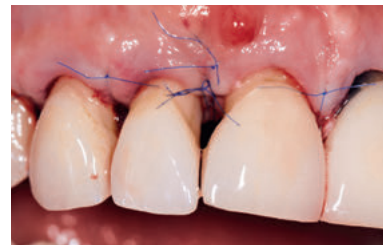**03** Surgical site after debridement and root planing.



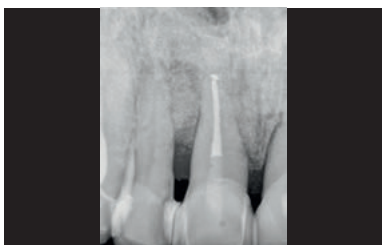**04** Defect fill with Geistlich Bio-Oss® after treatment with amelogenin derivative matrix.



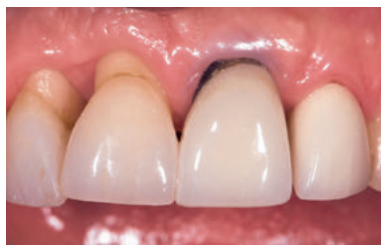**05** Coverage with Geistlich Bio-Gide® to stabilise the augmented area.



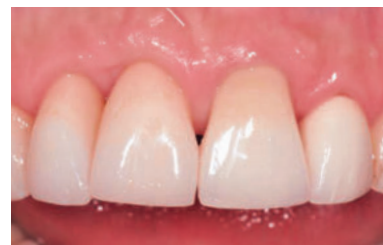**06** Situation after wound closure.



**07** 1 month after surgery an improvement of the bony situation is visible.



**08** Clinical situation after 5 months before closing the inter-approximate defect with composite.



**09** Final restoration 10 months after surgery.

**CONCLUSION** Successful preservation of two “hopeless” teeth with periodontal regenerative therapy.

# Regenerative surgery 11 – perio-endo

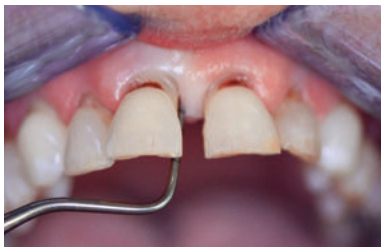SURGERY BY DR. SYED MAHNAZ, PERTH (AUS)



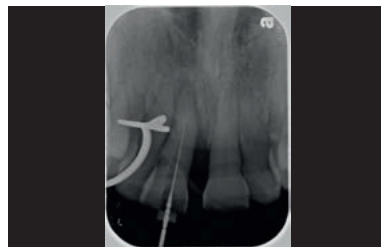**AIM** Retention of the central incisor and improvement of its mobility.

Tooth #	CAL (mm)		PD (mm)		Depth of bony defect (mm)	Defect morphology
	mesial	distal	mesial	distal		
11	9	5	7	4	4	2 wall defect
	buccal 5	lingual 5	buccal 3	lingual 3		

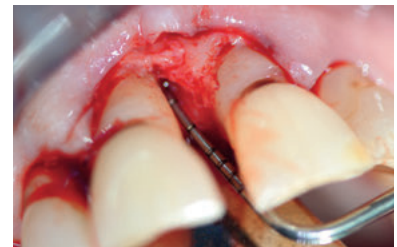<b>Biomaterials</b>	> Geistlich Bio-Oss®, Geistlich Bio-Gide®
<b>Suture material</b>	> Vicryl 5.0 suture materials
<b>Technique</b>	> Endodontic treatment followed by non-surgical debridement and a modified papilla preservation technique.
<b>Periodontal treatment</b>	> Nonsurgical periodontal debridement therapy under local anaesthesia with endodontic treatment was undertaken.



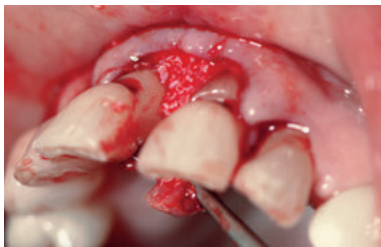**01** Non-responding residual pocket associated with a perio-endo involved tooth 11.



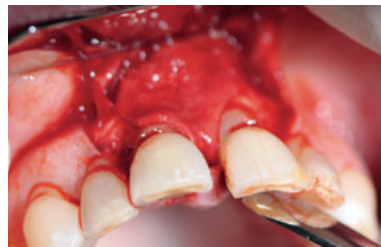**02** Radiograph of infrabony angular defect on tooth 11 with subsequent endodontic treatment.



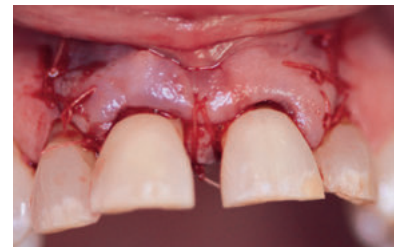
**03** Elevation of flap with papilla preservation to access the infrabony pocket.



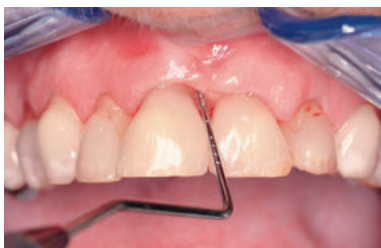**04** Geistlich Bio-Oss® granules in the defect.



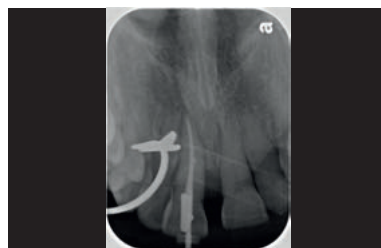**05** Geistlich Bio-Gide® membrane trimmed and placed in the interproximal region.



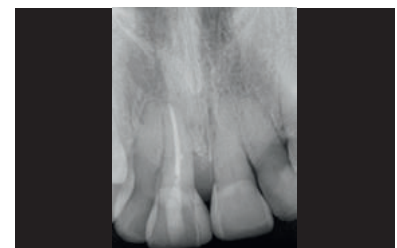**06** Immediate post-op passive closure and coronal repositioning of the mucosa.



**07** Improved pocketing and mobility 8 months after surgery and additional composite bonding to improve the aesthetics.



**08** Geistlich Bio-Oss® mesial of tooth 11 is well integrated after 8 months.



**08** Follow up 2 years post surgery showing good bone stability and improved clinical status of this tooth.

**CONCLUSION** Predictable treatment outcomes were achieved to help retain teeth in situations where perio-endo problems exist. Regenerative surgery offers sustainable options for treatment of advanced periodontal disease.

# 2-wall defect in the non-aesthetic region

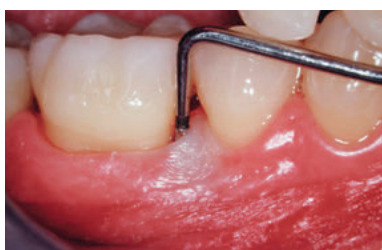SURGERY BY PROF. DR. GIULIO RASPERINI, MILAN (IT)



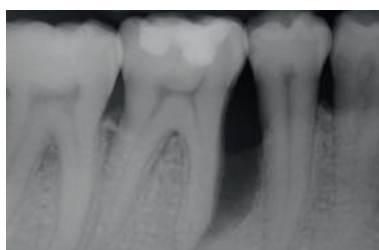
**AIM** Periodontal regeneration to reduce probing depth by increasing bone and periodontal attachment with a minimal gingival recession, to change the prognosis of the tooth # 46 and preserve its function.

Tooth #	CAL (mm)		PD (mm)		Depth of bony defect (mm)	Defect morphology
	mesial 14	distal 3	mesial 14	distal 3		
46	mesial 14	distal 3	mesial 14	distal 3	max 10	2 wall defect without furcation

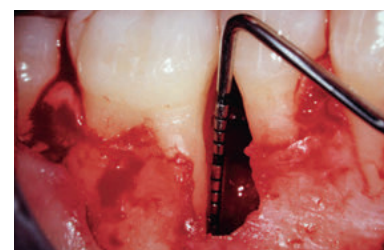<b>Biomaterials</b>	> Geistlich Bio-Oss®, Geistlich Bio-Gide®
<b>Suture material</b>	> Gore-Tex® Suture 5-0
<b>Technique</b>	> Periodontal regeneration procedure with preservation of the interdental tissue and mesial releasing incision.
<b>Periodontal treatment</b>	> Cause related periodontal therapy, including motivation and instructions for home care; professional supra-gingival debridement and sub-gingival root planing. Re-evaluation for potential additional therapy.



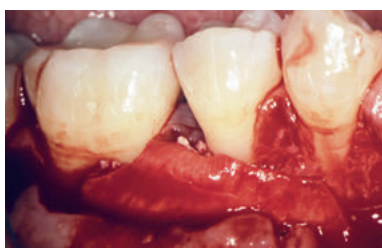**01** Baseline situation showing the 14 mm pocket depth mesial to tooth 46.



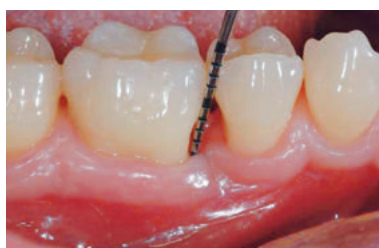**02** Baseline radiograph showing the presence of an angular bony defect involving the mesial site of tooth 46.



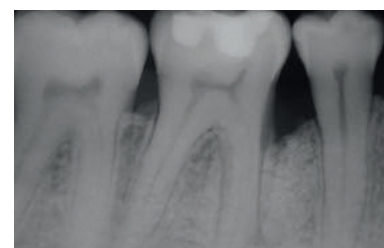
**03** Elevation of a full-thickness buccal and lingual flap with papilla preservation. The 10 mm deep, 2-wall intrabony defect mesial to tooth 46 is evident after careful debridement.



**04** The Geistlich Bio-Oss® fills the defect and is protected by a Geistlich Bio-Gide® membrane. After flap release, the wound is closed without tension.



**05** Re-evaluation at 1 year. A residual 5 mm probing depth is present with a 9 mm probing depth loss as compared to baseline measurements.



**06** Nearly complete bone fill of the angular defect at 1 year.

**CONCLUSION** 2 months after conclusion of presurgical, cause-related therapy, the patient reported the complete resolution of inflammation, resulting in a decrease of the full mouth plaque and bleeding scores. 1 year after the surgery, the soft-tissue was well preserved and represented with a sufficient width of keratinised gingiva. Radiographs after 1 year show a stable situation with an almost complete bone fill.



# Deep intrabony 2-wall defect

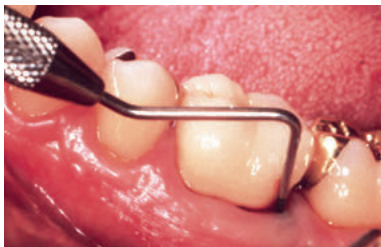SURGERY BY PROF. DR. ANTON SCULEAN, BERN (CH)



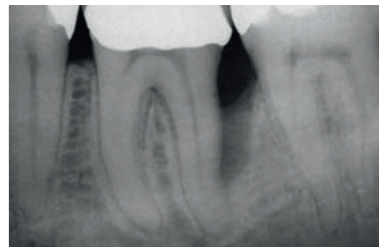
**AIM** Treatment of intrabony defect with a complicated, noncontained morphology using a combination of collagen barrier membrane and a natural bone mineral.

Tooth #	CAL (mm)	PD (mm)	Depth of bony defect (mm)	Defect morphology
36	distal 11	distal 11	5	2 wall, large non-contained defect

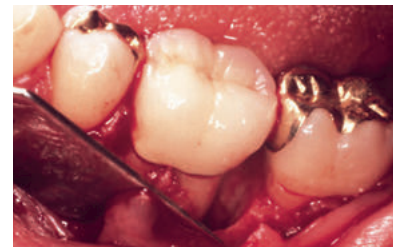<b>Biomaterials</b>	> Geistlich Bio-Gide® Perio, Geistlich Bio-Oss®
<b>Suture material</b>	> 4-0 silk
<b>Technique</b>	> Periodontal regeneration of a large non-contained defect through GTR with the use of grafting material.
<b>Periodontal treatment</b>	> Hygienic phase 3 months before regenerative surgery consisting of patient instruction for oral hygiene, and full-mouth scaling and root planing in conjunction with systemically administered antibiotic therapy (3 x 375 mg Amoxicillin and 3 x 250 mg Metronidazol) for one week.



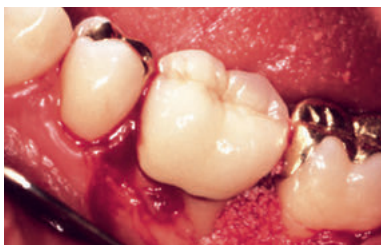**01** Preoperative probing indicating the presence of a deep pocket distal to the mandibular left molar.



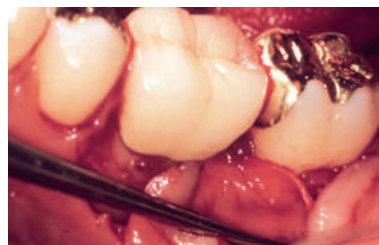**02** Preoperative radiograph demonstrating the extent of bone loss.



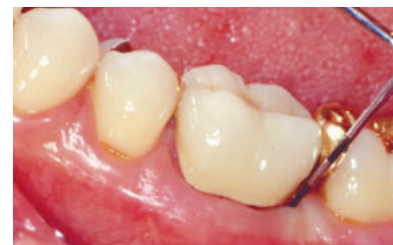**03** Intraoperative view revealing a deep non-contained intrabony defect.



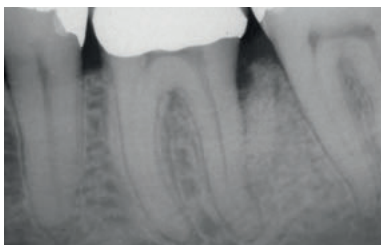
**04** Following removal of granulation tissue and root planing, the defect is filled with Geistlich Bio-Oss®.



**05** The grafting material and the surrounding alveolar bone are covered with a Geistlich Bio-Gide® Perio.



**06** Minimal recession of the soft tissues and attachment gain and reduced PD measured 6mm and 7 mm respectively at 1 year.



**07** Postoperative radiograph at 1 year reveals an almost complete fill of the intrabony defect.

**CONCLUSION** Good appearance of soft tissue and sufficient bone fill at 1 year after regeneration of a deep non-contained bony defect.



# 2-wall defect in the aesthetic zone

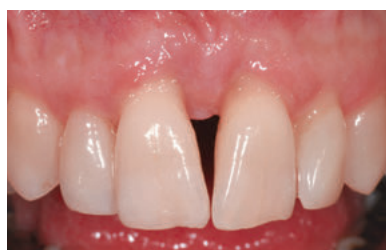SURGERY BY DR. BEAT WALLKAMM, LANGENTHAL (CH)



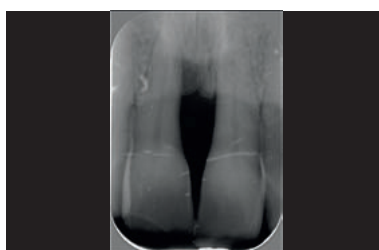**AIM** Periodontal regeneration with a minimally invasive surgical technique in combination with Geistlich Bio-Oss® Collagen and Geistlich Bio-Gide® Perio.

Tooth #	CAL (mm)		PD (mm)		Depth of bony defect (mm)	Defect morphology
11	mesial 11	distal 4	mesial 8	distal 3	5	2 wall defect
	buccal 4	lingual 4	buccal 2	lingual 3		

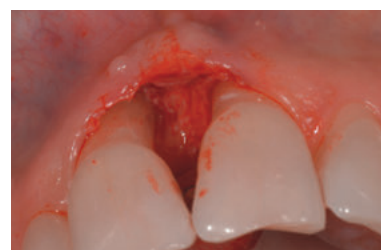<b>Biomaterials</b>	> Geistlich Bio-Oss® Collagen, Geistlich Bio-Gide® Perio
<b>Suture material</b>	> Seralene® 7/0 (PVDF, Serag Wiessner)
<b>Technique</b>	> Minimal invasive surgical technique (MIST) (Cortellini 2009)
<b>Periodontal treatment</b>	> Initial periodontal treatment (4hrs), 3-months recall



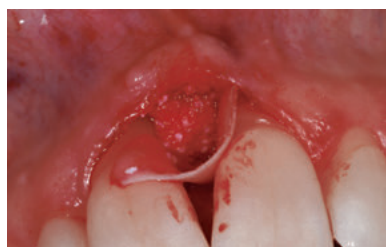**01** Tooth 11 presents with a pocket depth of 8 mm and a clinical attachment level of 11 mm with some loss of papillary tissue.



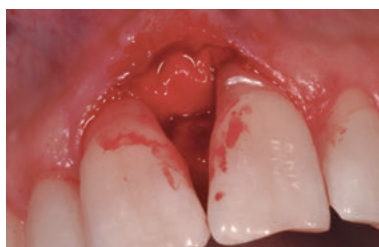**02** Baseline radiograph shows the bone loss mesially to the first right incisor reaching the apical third of the root.



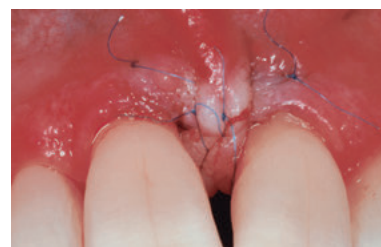**03** After elevation of a tiny buccal flap and positioning of the interdental papilla slightly to the palatal side, the defect is debrided.



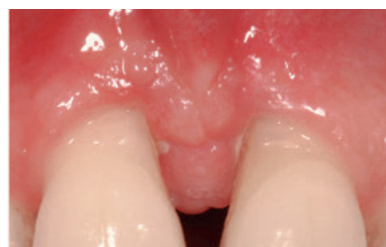**04** A trimmed Geistlich Bio-Gide® Perio is inserted lingually and Geistlich Bio-Oss® Collagen is applied into the defect.



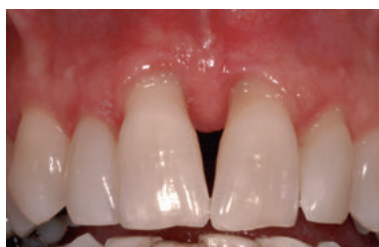**05** The Geistlich Bio-Gide® Perio is folded over the augmented site and inserted under the buccal full thickness flap.



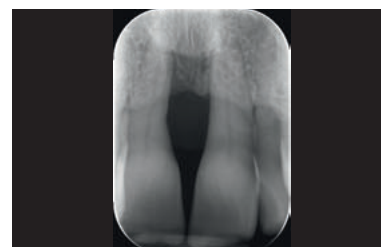**06** Primary closure of the wide interdental papilla is obtained with an internal mattress suture with an external loop and two oblique hang-up mattress sutures.



**07** 6 weeks after surgery the inter-dental soft tissues are well healed.



**08** Clinical situation after 2 years with a probing pocket depth of 3 mm and a clinical attachment level gain of 5 mm.



**09** The 2 year radiograph shows a horizontal gain of 3 mm bone in the treated area.

**CONCLUSION** The minimally invasive surgical technique in combination with Geistlich Bio-Oss® Collagen and Geistlich Bio-Gide® Perio resulted in markedly improved clinical and radiographic outcome.

**Reference**

Cortellini P, Tonetti MS. Improved wound stability with a modified minimally invasive surgical technique in the regenerative treatment of isolated interdental intrabony defects. J Clin Periodontol 2009; 36: 157-163.

# 2-wall wide intrabony defect

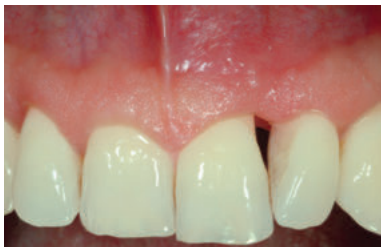SURGERY BY PROF. DR. GIOVANNI ZUCHELLI, BOLOGNA (IT)



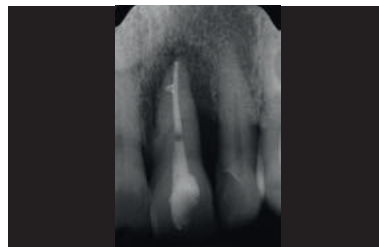
**AIM** Regenerative surgery of a severely compromised tooth in aesthetic area.

Tooth #	CAL (mm)		PD (mm)		Depth of bony defect (mm)	Defect morphology
	mesial 3	distal 13	mesial 3	distal 11		
21	mesial 3	distal 13	mesial 3	distal 11	13	combined intrabony defect
	buccal 11	lingual 3	buccal 11	lingual 3		

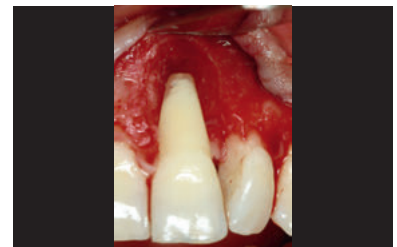<b>Biomaterials</b>	> Geistlich Bio-Oss®, Geistlich Bio-Gide®, Amelogenin
<b>Suture material</b>	> PGA 7.0 in the papilla / PGA 6.0 in the flap
<b>Technique</b>	> Regenerative surgery with CAF combined with simplified papilla preservation
<b>Periodontal treatment</b>	> Ultrasonic periodontal therapy before the surgery



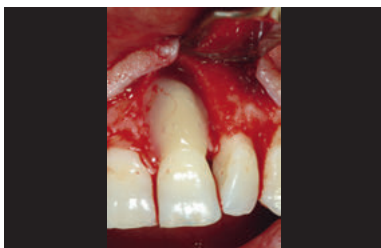**01** Pre-operative view of the affected upper left incisor.



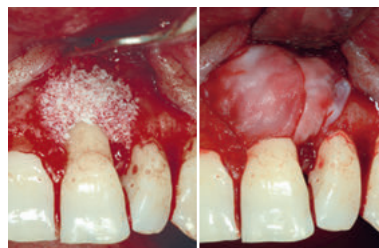**02** Radiographic situation before treatment. The wide defect reaches the apex of the tooth.



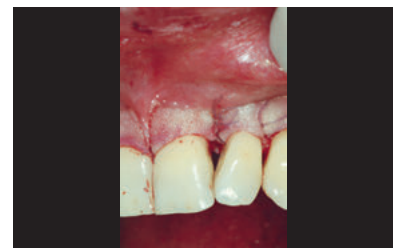**03** The defect after degranulation.



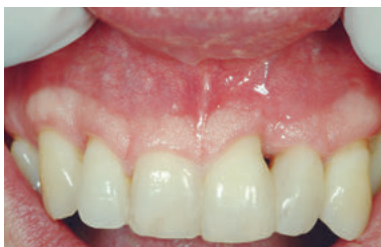**04** EDTA and an amelogenin derivative matrix are applied to condition the root surface.



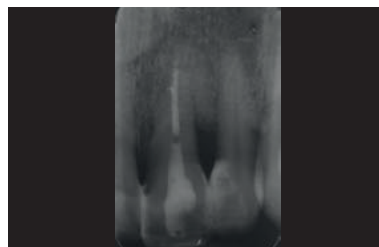
**05** Geistlich Bio-Oss® fills the wide defect and Geistlich Bio-Gide® prevents tissue collapse while stabilizing the site.



**06** Post-op view of suturing: note the primary intention closure of the interdental papilla above the defect.



**07** Clinical situation at 12 month follow-up. A regrowth of the interdental papilla could be achieved.



**08** Follow-up radiograph at 12 months reveals complete bone fill.

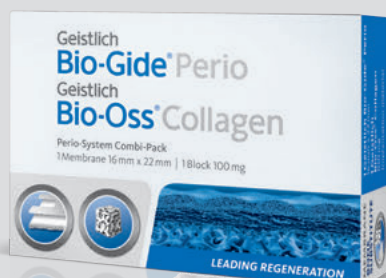**CONCLUSION** Healthy hard- and soft-tissue situation with regrowth of the interdental papilla after 1 year.

## References:

- <sup>1</sup> Wang HL et al., J Periodontol. 2005 Sep; 76(9):1601-1622
- <sup>2</sup> Sculean A et al., J Clin Periodontol. 2007 Jan;34(1):72-77
- <sup>3</sup> Holm-Pederson et al, Clin. Oral Impl. Res. 18 (Suppl. 3), 2007 / 15-19
- <sup>4</sup> Donos N et al., Periodontol 2000. 2012 Jun;59(1):89-110
- <sup>5</sup> Zitzmann NU et al., Int Endod J. 2009 Sep;42(9):757-774
- <sup>6</sup> Checchi L et al., J Clin Periodontol. 2002 Jul; 29(7): 651-656
- <sup>7</sup> Samet N et al., Quintessence Int. 2009 May; 40(5):377-387
- <sup>8</sup> Becker W et al., J Periodontol. 1984 Sep; 55(9):505-509
- <sup>9</sup> Newman, Takei, Klokkevold, Carranza. CARRANZA'S CLINICAL PERIODONTOLOGY. ISBN 13 978-1-4160-2400-2.
- <sup>10</sup> Lindhe, Karring, Lang. Clinical Periodontology and Implant Dentistry. BlackwellMunksgaard. ISBN 1-4051-0236-5.
- <sup>11</sup> Rateitschak, Wolf. Farbatlanten der Zahnmedizin 1. Parodontologie. Thieme. ISBN 3-13-655601-1.
- <sup>12</sup> Cortellini P. et al., J Clin Periodontol. 2011 Oct;38(10):915-924
- <sup>13</sup> Cortellini P., Tonetti MS., J Periodontol. 2004 May;75(5):672-678
- <sup>14</sup> Sculean A. et al., J Clin Periodontol. 2008 Sep;35(9):817-824
- <sup>15</sup> Kinaia BM. et al., J Periodontol. 2011 Mar; 82 (3):413-428
- <sup>16</sup> Sculean Anton. Periodontal Regenerative Therapy. Quintessence Publishing. ISBN-13: 9781850971580
- <sup>17</sup> Papapanou PN., Tonetti MS., Periodontol 2000. 2000 Feb;22:8-21
- <sup>18</sup> Reddy KP et al., J Contemp Dent Pract. 2006 Feb 15;7(1):60-70
- <sup>19</sup> Ghezzi et al Clin. Oral Impl. Res. 18 (Suppl. 3), 2007 / 15-19
- <sup>20</sup> Murphy KG et Gunsolley JC, Ann Periodontol, Dec, 2003, Vol 8. Number 1, 266-302
- <sup>21</sup> Houser BE et al., Int J Periodontics Restorative Dent., 2001 Apr, 21 (2): 161-169
- <sup>22</sup> Paolantonio M et al., J Periodontol. 2010 Nov;81(11):1587-1595
- <sup>23</sup> Da Silva VC et al., J Clin Periodontol. 2006 Jun;33(6):440-448
- <sup>24</sup> Cardaropoli D et al., Int J Periodontics Restorative Dent. 2006 Dec;26(6):553-559
- <sup>25</sup> Cosyn J et al., J Clin Periodontol. 2012; Oct;39(10):979-986
- <sup>26</sup> Camelo Int J Periodontics Restorative Dent. 1998 Aug;18(4):321-331
- <sup>27</sup> Lundgren D, Slotte C, J Clin Periodontol. 1999 Jan;26(1):56-62
- <sup>28</sup> Camargo PM et al., J Clin Periodontol. 2000 Dec;27(12):889-896
- <sup>29</sup> Sculean A et al., J Clin Periodontol. 2003 Jan;30(1):73-80
- <sup>30</sup> Tonetti MS et al., J Clin Periodontol. 2004 Sep;31(9):770-776
- <sup>31</sup> Liñares M et al., J Clin Periodontol. 2006 May;33(5):351-358

## Adding convenience to periodontal treatments!

SIMPLE TO HANDLE, SIMPLE TO SHAPE



### Perio-System Combi-Pack

Geistlich Bio-Oss®  
Collagen 100 mg

Geistlich Bio-Gide® Perio  
with sterile templates  
16 x 22 mm



## Product Range for periodontal treatment \*



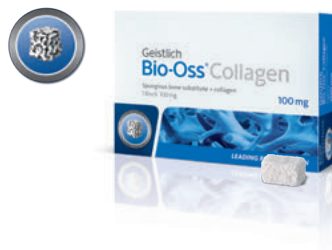**Geistlich Bio-Gide® Perio**  
Resorbable bilayer membrane  
with sterile templates

Available sizes:  
16 mm x 22 mm



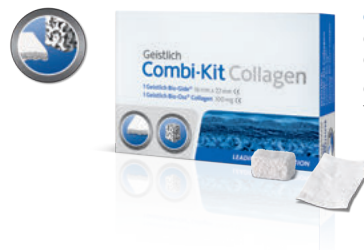**Geistlich Bio-Gide®**  
Resorbable bilayer membrane

Available sizes:  
25 mm x 25 mm  
30 mm x 40 mm



**Geistlich Bio-Oss® Collagen**  
Spongius bone substitute  
Preformed block with Collagen

Available sizes:  
100 mg  
250 mg  
500 mg



**Geistlich Combi-Kit Collagen**

Geistlich Bio-Oss®  
Collagen 100 mg  
Geistlich Bio-Gide®  
16 x 22 mm



**Geistlich Bio-Oss®**  
Spongius bone substitute  
Small granules 0.25 mm – 1 mm

Available sizes:  
0.25 g = 0.5 cc  
0.5 g = 1 cc  
2 g = 4 cc



**Geistlich Bio-Oss®**  
Spongius bone substitute  
Large granules 1 mm – 2 mm

Available sizes:  
0.5 g = 1.5 cc  
2 g = 6 cc

\* Product availability may vary from country to country.

### Subsidiary Great Britain, Ireland

Geistlich Biomaterials  
Geistlich Sons Limited  
1<sup>st</sup> Floor, Thorley House  
Bailey Lane, Manchester Airport  
GB-Manchester M90 4AB  
Phone +44 1 614 902 038  
Fax +44 1 614 986 988  
www.geistlich.co.uk

### Manufacturer

© Geistlich Pharma AG  
Business Unit Biomaterials  
Bahnhofstrasse 40  
CH-6110 Wolhusen  
Phone +41-41-4925 630  
Fax +41-41-4925 639  
www.geistlich-pharma.com